

PAPER • OPEN ACCESS

Testing of therapeutic and hygienic agents in prevention and treatment of diseases of cow hooves

To cite this article: V G Semenov *et al* 2020 *IOP Conf. Ser.: Earth Environ. Sci.* **433** 012026

View the [article online](#) for updates and enhancements.

Testing of therapeutic and hygienic agents in prevention and treatment of diseases of cow hooves

V G Semenov^{1,*}, A V Chuchulin¹, D A Baimukanov², V G Sofronov³, A Kh Volkov³, N K Kirillov¹ and A V Aldyakov¹

¹Faculty of Veterinary Medicine and Animal Science, *Chuvash State Agricultural Academy*, 29 K. Marx Street, Cheboksary, 428003, Russia

²Department of Physiology, Morphology, and Biochemistry named after Academician Neyli Urazaevna Bazanova, *Kazakh National Agrarian University*, 8 Abay Avenue, Almaty, 050010, Republic of Kazakhstan

³Faculty of Veterinary Medicine, *Kazan State Academy of Veterinary Medicine named after N.E. Bauman*, 35 Siberian Tract Street, Kazan, 420029, Russia

*E-mail: semenov_v.g@list.ru

Abstract. The purpose of this work is to test medical and hygienic agents for prevention and therapy of diseases of cow hooves. The objects of research were five groups of black-and-white cows of ten heads each with various forms of lesions with digital dermatitis. Animals of the 1st experimental group were passed through disinfection bath with 10% aqueous solution of CuSO₄ twice a week, in the treatment of finger dermatitis of cows of the 2nd, 3rd and 4th experimental groups, respectively, therapeutic and hygienic means Solka, Espuarol-Gel and Espuarol-Sin were used. The hematological indices of cows of the 3rd experimental group against the background of the use of Espuarol-Gel entered physiological norms earlier than those of their peers of the 2nd and 4th experimental groups, in the treatment of hoof diseases of which they used Solka and Espuarol-Sin. Espuarol-Gel tested in leading cattle-breeding enterprises of the Chuvash Republic and the Republic of Tatarstan has a more pronounced therapeutic effect, providing a bactericidal effect on pathogens of cow hoofs, expressed in a decrease in the total group assessment of limb condition by 8.9%, the total claudication score by 13.7 %, and the total diameter of lesions by 4.1%, rather than Espuarol-Sin.

1. Introduction

The modern dairy industry is plagued by a high prevalence of claw horn lesions in cows, which cause lameness, affect well-being, limit milk production, and are responsible for premature removal of cows from the herd [1].

Foot lesions are one of the main causes of productivity losses in the dairy industry. Hoof examination, lesion classification, and hoof trimming were performed on 492 animals including lameness and had foot lesions, 81.4% of which were observed in the pelvic limbs and 19.6% in the thoracic limbs, where 47.1% of the limb lesions were originally infected [2]. The main lesions were sole ulcers (31.6%), digital dermatitis (30.3%), thin soles (12%), and interdigital dermatitis (11.2%). Preventive hoof trimming reduced the chances of lameness by 55% as the locomotive system was the main sanitary problem and the first reason for involuntary disposal of the farms. The results show that dairy cows raised in a free stall system have a high prevalence of claudication and foot diseases.

Lameness is a severe welfare problem in cattle and has a detrimental effect on longevity,



Content from this work may be used under the terms of the [Creative Commons Attribution 3.0 licence](https://creativecommons.org/licenses/by/3.0/). Any further distribution of this work must maintain attribution to the author(s) and the title of the work, journal citation and DOI.

productivity, and reproductive performance. Non-infectious foot lesions were more common than infectious (94.4 vs 5.6%). White line disease was more frequently observed in the hind limbs (79.6%) compared to the front limbs (20.4%), and more frequent in medial claws of the front limbs (70.3%) compared to lateral claws (29.7%). In hind limbs, the lateral claws were more commonly affected (65.7%) compared to the medial claws (34.3%). Claw zone 3 was affected in 61.3% of the cases, followed by zones 2 (21.7%) and 1 (17%). Although our data are from a limited area of the country, they are consistent with published and anecdotal reports of foot lesions in cattle in Colombia and worldwide [3].

Hoof pathologies in dairy cows have a major effect on both production and animal welfare. Trimming of excess or diseased hoof tissue is essential for the treatment of many of these conditions [4]. Globally, lameness is widespread in dairy cattle herds. Up to 25% of highly productive cows in the herd can limp at the same time, which causes significant damage, affecting mainly milk production, and leads to financial losses. From animals with deformed hooves, even without signs of lameness, farms receive less than 4-14% of milk, on average, the offspring decreases by 17%. Predisposing factors of diseases of the distal extremities, such as unfavorable housing conditions, disturbances in feeding, reduced body resistance, hereditary anomalies in the structure of the extremities, leading to premature annual culling of 15% of dairy cows [5].

Many hoof diseases are associated with the lack of proper care. This is especially associated with deformities, improper limb setting, delayed treatment, and inappropriate preventive measures to combat secondary infection and injuries. All of the above factors lead to the emergence of the pathology of the keratinization process of the hoof horn, and, in addition, reduce the body's ability of animals to natural resistance, in particular to infections [6, 7].

A constant high percentage of culling of animals indicates a complex, multifactor etiology of limb lesions, which has an organizational, infectious and non-infectious nature, a lack of effectiveness of therapeutic and preventive measures and used tools and veterinary drugs [8, 9].

There are not enough specialists in this area even in advanced farms, and in ordinary ones, this problem is "not noticed" until it is manifested "to the full" [10, 11].

The purpose of this work is to test the therapeutic and hygienic means for the prevention and treatment of diseases of the hooves of cows; development of a system for the prevention of lameness and treatment of diseases of the hooves of cows

2. Materials and methods

The experimental part of the research work was carried out on the dairy farm of JSC APK "Chebakovo" of the Yadrinsky District of the Chuvash Republic, and the materials were processed at the Department of Morphology, Obstetrics, and Therapy at the Chuvash State Agricultural Academy (Cheboksary, Russia).

The objects of research were five groups of black-and-white cows of 10 heads each with various forms of lesions with digital dermatitis. Animals of the control group were not treated, cows of the 1st experimental group were passed through disinfection bath with 10% aqueous solution of CuSO₄ twice a week, in the treatment of finger dermatitis of cows of the 2nd, 3rd and 4th experimental groups, respectively, therapeutic and hygienic means Solka, Espuarol-Gel and Espuarol-Sin were used.

Solka (Kanters Special Products B. V., De Stater 32, 5737 RV Lieshout, Netherlands) is a blue gel containing copper and zinc in chelated form, organic acids, adhesive components, and formative substances. The chelated form of copper and zinc determines a higher antimicrobial and wound-healing activity of the drug compared to inorganic forms, provides resistance to manure, dampness, and temperature. Organic acids contained in the gel have an antimicrobial effect, provide a good penetrating ability of the drug. The gel has adhesive properties, its activity is maintained after contact with manure and in conditions of high humidity.

Espuarol-Gel (Belgorodskaya Veterinary Company, Russia) is a yellow-orange gel, an antibacterial, wound-healing preparation for the care of hooves. Espuarol-Gel as an active ingredient contains a chelate complex of lanthanide salts, the sodium salt of benzoic acid, benzyl dimethyl myristoyl

aminopropyl ammonium chloride, and as auxiliary components – tween-80 (TOS, Russia), polyethylene glycols (Organic synthesis, Russia), distilled water (pH=5.4-6.6, conductivity $\sim 5 \times 10^{-4}$ Sm/m). The chelate complex of salts of lanthanides has a dermatotropic and wound-healing effect, increases the phagocytic activity of blood leukocytes. Quaternary ammonium salt has a wide spectrum of antimicrobial action. The mechanism of action is the destruction of the microbial cell. The sodium salt of benzoic acid has a bactericidal effect. Auxiliary substances are pH-neutral buffer systems that provide good adhesiveness and penetration ability of active substances.

Espuarol-Sin (Belgorodskaya Veterinary Company, Russia) – gel from blue-green to dark blue, contains organometallic complex as active substances, the sodium salt of benzoic acid (China), 1,3-dichloro 5,5-dimethylhydantoin (China), and as an auxiliary – polysorbate-80 (TOS, Russia), polyethylene glycols (Organic synthesis, Russia), glycerin (Nefis Cosmetics JSC, Russia), and distilled water. The organometallic complex has a dermatotropic and wound-healing effect, increases the phagocytic activity of blood leukocytes; 1,3-dichloro 5,5-dimethylhydantoin is one of the most active antiseptic agents, has a bactericidal effect.

Therapeutic and functional pruning of cows' hooves was performed by the Dutch flat method in 5 stages: modelled cow hooves

- 1) the cow was fixed in the machine; cleared the hooves of dirt and manure; measured the length of the inner claw from the rim to the hook, made a notch of the correct length (7.5 cm) and trimmed; level the surface of the sole; the thickness at the tip of the sock was left 5-7 mm;

- 2) trimmed the cow's external hoof; leveled the surface of the sole; checked the height of the inner and outer hooves, they should be the same;

- 3) gave the correct slope between the hooves, removed the dead stratum corneum on the heel;

- 4) modeled cow hooves, giving the correct shape;

- 5) medical hygiene products were applied to the affected areas of the hoofs with a brush (Solka, Espuarol-Gel, Espuarol-Sin).

Limb control for each group of cows was performed 3 times at 2 week intervals. The method developed by D. Döpfer [12] was used to evaluate the state of distal limb dress and its changes during the experiments, which provides for the quantitative evaluation of changes caused by the development of infectious finger dermatitis. The count of the lame animals was carried out according to the procedure in [13], which consists in a ballroom assessment of the degree of chromness based on the state of the back (straight or curved) in the standing position and when walking: 1 point – chromot is absent, 2 points (light chromote) – a cow stands with a straight back, but walks with a curved back and takes shorter steps; it does not focus on any particular limb; 3 points (moderate limp) – a cow stands and walks with a curved back, moves short steps, on the damaged leg gives less load, lowers the head when the weight is transferred to the affected limb; 4 points (severe limp) – a cow stands and walks with a curved back, the limp is visible clearly, the cow moves slowly, often stops; 5 points (extreme degree of limp) – cows show extreme reluctance to load the affected limb.

Clinical evaluation of the intensity of lesions in finger dermatitis was carried out according to the classification proposed in [14] which consists in dividing the course of the disease into 4 different stages: M1 – lesions of small size (less than 2 cm) with red or white-red surface, exudation is possible, epithelium can be preserved or damaged; M2 – "classical ulceration," red or white-red lesions with diameter more than 2 cm, on the surface of the lesion granulation or proliferative tissue (in large quantity or filamentous); M3 – healing lesions with black slupeyed surface; M4 – characterized by disceratoses or proliferation.

Erythrocyte count was determined, hemoglobin concentration, total leukocyte count, and by species on the PCE 90 Vet automated veterinary hematology analyzer (Erma Inc., Japan).

3. Research results

Complex treatment of finger dermatitis in cows of the 3rd experimental group with Espuarol-Gel is shown in figures 1 and 2. For a more pronounced effect, it is desirable to leave the animal fixed in the machine for a few minutes (figure 3). In the event of severe injury to the extremities, the affected area

is covered with parchment paper and tapered with metalized scotch tape for no more than 48 h (figure 4). The duration of the procedures is set individually, depending on the nature, duration, and severity of the disease.

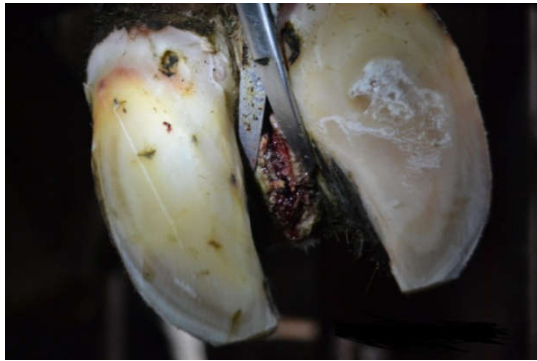

Figure 1. Cleaning and removing the dead horn.

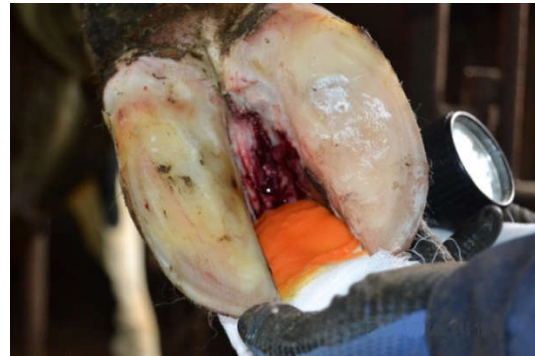

Figure 2. Swabbing with Espuarol-Gel.



Figure 3. Bandaging of the affected area.

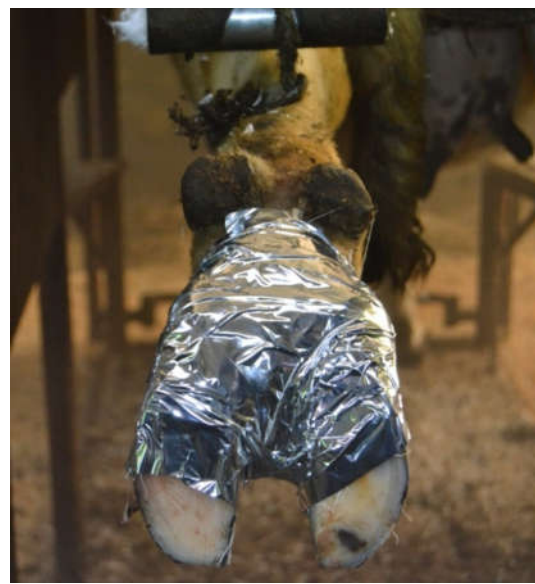

Figure 4. Bandaging with metallic tape.

The total group score assessment of the limbs state for the animal experimental groups at the beginning and end of the experiment differ significantly. In the control group and in the group with the use of baths with CuSO_4 limb deterioration was +126 points (79.4%) and +62 points (35.4%), respectively (figure 5). In the 2nd, 3rd and 4th experimental groups using Solka gels, Espuarol-Gel, and Espuarol-Sin gels showed an improvement in the condition of the extremities, which in the ball system was reduced by 184 points (63.2%), 211 points (80.8%) and 192 points (71.9%), respectively (figure 5).

It was established that in the control and 1st experimental groups the degree of lameness increased by +7 points (77.7%) and +2 points (15.3%), respectively (figure 6). In groups using Solka, Espuarol-Gel and Espuarol-Sin gels, the degree of lameness decreased by 6 points (35.3%), 8 points (47.0%) and 5 points (33.3%), respectively (figure 6).

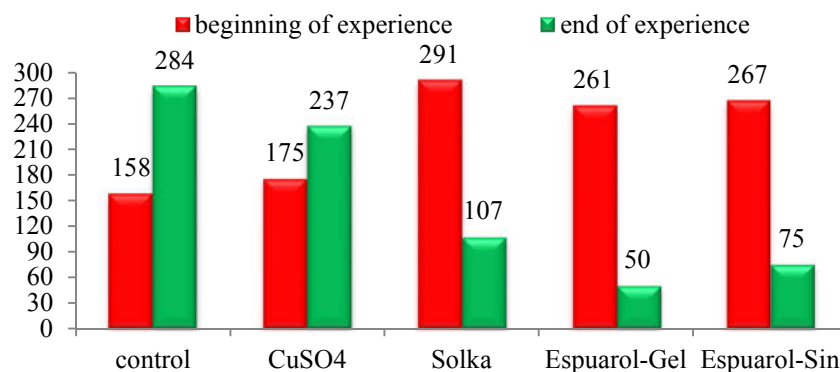


Figure 5. Total group assessment of limb condition.

It was established that in the control group and the 1st experimental group with the use of CuSO₄ baths there was an increase in the total diameter of the affected areas with digital dermatitis + 11 mm (7.7%) and +3 mm (2.3%), respectively. In the 2nd, 3rd and 4th experimental groups using Solka gels, Espuarol-Gel, and Espuarol-Sin gels, this indicator decreased by 61 mm (31.7%), 69 mm (36.9%) and 62 mm (32.8%), respectively (figure 7).

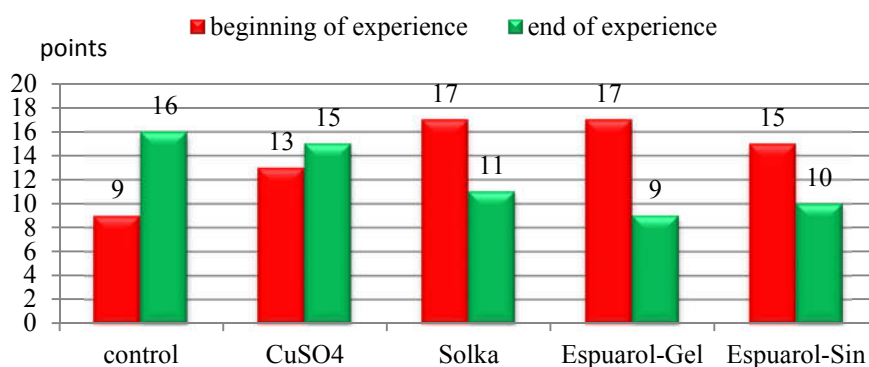


Figure 6. Dynamics of the total group score of the chromote.

Thus, a study of the comparative effectiveness of therapeutic and hygienic means has revealed a more pronounced therapeutic effect of the tested drug Espuarol-Gel: it provides a bactericidal effect on pathogens of cow hooves and expresses a decrease in the total group assessment of limb condition by 8.9%, the total claudication score by 13.7%, and the total diameter of lesions by 4.1%, rather than Espuarol-Sin.

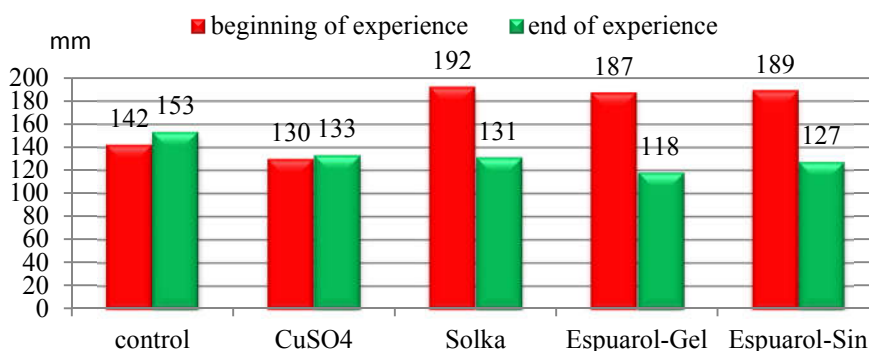


Figure 7. Dynamics of total group diameter of finger dermatitis lesions, mm.

It was established that cows in the experimental groups before treatment had leukocytosis exceeding physiological norms, with a pronounced shift of the leukocyte formula to the left (table 1). An increase in the number of stab neutrophils was 2.0-2.5 times higher than the upper limit of the physiological norm, a decrease in the number of segmented neutrophils, an increase in the number of monocytes by 30-40% higher than the upper limit of normal. On the 14th day after the therapeutic measures, the normalization of the hematological profile of cows of the 2nd, 3rd, and 4th experimental groups was established.

Table 1. Leukogram of cow blood.

Indicator	control	Experimental groups			
		1 st	2 nd	3 rd	4 th
before treatment					
Basophils, %;	1.6±0.20	1,7±0.20	1.6±0.20	1.8±0.20	1.7±0.19
Eosinophils	5.1±0.37	4.9±0.24	4.8±0.22	4.6±0.37	4.7±0.39
<i>Immature</i> neutrophil, %	5.4±0.22	6.1±0.37	5.6±0.49	5.9±0.24	5.7±0.33
<i>banded neutrophil</i> , %	9.7±0,40	9.3±0.40	9.5±0.51	9.9±0.40	9.6±0.43
<i>segmented neutrophil</i> , %	19.3±0,60	19.8±0.60	18.9±0.60	19.2±0.68	19.3±0.63
Lymphocytes, %	52.1±0.49	51.0±0.68	52.6±0.68	50.5±0.68	51.5±0.63
Monocytes, %	6.8±0.22	7.2±0.22	7.1±0.20	8.1±0.37	7.5±0.27
White blood cells, ×10 ⁹	12.9±0.20	13.5±0.37	12.7±0.37	13.2±0.49	12.9±0.51
14 th day					
Basophils, %;	1.5±0.20	1.3±0.22	1.0±0.20	-	-
Eosinophils	4.9±0.22	5.1±0.37	5.1±0.22	4.4±0.22	4.8±0.27
<i>Immature</i> neutrophil, %	5.8±0.22	4.6±0.24	4.1±0.22	2.2±0.20	2.1±0.22
<i>banded neutrophil</i> , %	9.7±0.37	7.9±0.40	7.1±0.24**	6.6±0.37**	6.9±0.33**
<i>segmented neutrophil</i> , %	20.3±0.60	22.7±0.22	22.3±0.37*	26.3±0.40**	26.1±0.39**
Lymphocytes, %	50.7±0.68	51.2±0.60	53.8±0.68	53.3±0.51	53.0±0.61
Monocytes, %	7.1±0.40	7.2±0.24	6.6±0.22*	7.8±0.22**	7.1±0.25*
White blood cells, ×10 ⁹	12.7±0.24	10.7±0.37	9.9±0.49	9.2±0.49	9.5±0.39
28 th day					
Basophils, %;	1.9±0.22	0.7±0.20	0.7±0.20	1.0±0.20	1.0±0.20
Eosinophils	4.8±0.37	5.2±0.22	5.2±0.22	5.7±0.20	5.5±0.23
<i>Immature</i> neutrophil, %	5.3±0.20	3.8±0.22	1.3±0.20*	0.9±0.22**	1.6±0.24*
<i>banded neutrophil</i> , %	10.1±0.37	7.2±0.37	5.8±0.37*	4.7±0.37*	4.9±0.33*
<i>segmented neutrophil</i> , %	19.9±0.60	23.1±0.40	25.7±0.24**	26.9±0.60**	26.2±0.63**
Lymphocytes, %	50.8±0.68	52.9±0.60	56.8±0.60*	55.7±0.24*	55.9±0.25*
Monocytes, %	7.2±0.37	7.1±0.22	4.5±0.24*	5.1±0.22*	4.9±0.27*
White blood cells, ×10 ⁹	10.4±0.22	9.4±0.37	8.3±0.37*	7.6±0.22**	7.6±0.25**

Thus, after carrying out therapeutic measures, normalization of hematological profile of cows of the 2nd, 3rd and 4th experimental groups was established. At the same time, Espuarol-Gel had a more pronounced corresponding effect than Solka and Espuarol-Sin.

For the prevention and therapy of diseases, cow hooves offer to use the medicinal and hygienic tool Espuarol-Gel. It has a more pronounced preventive and therapeutic effect, providing a bactericidal effect on pathogens of cow hooves, which results in a decrease in the total group assessment of limb condition by 8.9%, the total claudication score by 13.7%, and the total diameter lesions by 4.1% than Espuarol-Sin.

4. Conclusion

In light of the above, based on our experimental studies, we offer veterinary and hygienic methods for the prevention of lameness and the treatment of diseases of hoofs in cattle, which includes hygiene of maintenance, feeding, and care, functional pruning of the hooves by the Dutch flat method on a hand-

developed machine tool and the use of the medicinal and hygienic means with the dermatotropic effect Espuarol-Gel.

Optimal microclimate should be maintained in the cow premises. At high humidity and dampness of the floor, the hoof horn is more washed and less resistant to damage, and at low humidity, it loses elasticity, cracks, partly breaks. Therefore, in case of low air humidity, animals should be passed through foot baths with water, or be passed over dew.

It is necessary to observe hygienic conditions of keeping and feeding animals, which provides non-specific resistance of the body to pressing of ecological-technological factors of habitat, prevents injuries and diseases of hoof. In order to prevent laminitis, it is important to reduce the content of feed in the diet of cows in the dry period; the presence of a sufficient number of high-quality roughage; a gradual increase in the amount of feed in the diet after calving.

Recreation area of animals should be equipped with solid wooden floors, and with slatted floor in the area of defecation. Leveled and dried surfaces inside and outside the barn make walking easier and cause less limp problems. In order to prevent injuries to the limbs of animal fine sand should be added in the upper concrete layers of the coverless concrete floors structures so that cement and sand wore evenly. Incorrectly cast concrete floors adversely affect the degree of growth and wear of the stratum corneum.

When selecting animals in a herd, special attention should be paid to the appearance and condition of the hooves, their shape, strength, and quality of the horns, and select the servicing bulls that improve the quality of the limbs. It is necessary to provide animals with active motion up to 5 km for normal growth and wear of the horny layer of hooves. In the prevention of diseases of the hooves, as a hygienic procedure, foot baths of size 3.5x1 m, height 15 cm, with rounded sides are practiced. They are filled with a 10% solution of copper sulfate, a 10% solution of zinc sulfate, a 5% solution of formalin or formaïod, iodine-polymer Monclavit-1 or a 3% solution of HoofSmart Bath to a depth of 10-12 cm. Animals are passed through foot baths twice in 2 days with an interval of three to four weeks. In rooms for young animals during periods of rearing and fattening, it is recommended to disinfect the floor and at the same time the animals' hooves with a 0.5-1% solution of potassium permanganate or active foam in 2 stages, formed by mixing two components Kovex Foam Activator and Kovex Foam Blitz, twice a year.

In order to strengthen the hoof horn, cows are fed 3.0 g of sulfur per 100 kg of live weight, in a group way mixed with mixed feed. The regular orthopedic medical examination allows detecting damage to the hooves and provides effective therapeutic care, avoiding serious complications. In case of stall-grazing system, it is recommended to carry out functional pruning of hooves twice a year, before going to pasture and when setting up for winter-stall housing, and in case of year-round stall system - in 3-4 months.

We recommend antibacterial and wound-healing preparations Solka, Espuarol-Gel, and Espuarol-Sin as therapeutic and hygienic means for treating hooves of cows. Our proposed veterinary and hygienic methods for the prevention and treatment of diseases of the hooves of cattle hooves are introduced in the Chekakovo AIC, Yadrinsky District, and Bezdna LLC, Morgaushsky District, Chuvash Republic in Russia.

5. Acknowledgments

The research work was supported by the Foundation for Assistance to the Development of Small Forms of Enterprises in the Scientific and Technical Sphere based on the results of the XIII Republican Contest of Innovative Projects under the Program "Participant of the Youth Scientific and Innovation Contest" (Russia).

References

- [1] Nuss K, Müller J and Wiestner T 2019 Effects of induced weight shift in the hind limbs on claw loads in dairy cows. *J. Dairy Sci.* **102** (7) 6431
- [2] Ebling R C, Krummenauer A, Machado G, Carazzo L P and Do Rêgo M L 2019 Leal Prevalence

- and distribution of feet lesions in dairy cows raised in the freestall. *Semina: Ciencias Agrarias* **40** (1) 239
- [3] Correa-Valencia N M, Castaño-Aguilar I R, Shearer J K, Arango-Sabogal J C and Fecteau G 2019 Frequency and distribution of foot lesions identified during cattle hoof trimming in the Province of Antioquia, Colombia (2011–2016). *Trop. Anim. Health Pro.* **51** (1) 17
 - [4] Stilwell G T, Ferrador A M, Santos M S, Domingues J M and Carolino N 2019 Use of topical local anesthetics to control pain during treatment of hoof lesions in dairy cows. *J. Dairy Sci.* **102**(7) 6383
 - [5] Veremey E, Zhurba V, Rukol V, Stekolnikov A and Semenov V 2017 The care of hooves. *Animal Husbandry of Russia* **3** 29
 - [6] Gimranov V V, Uteev R A and Gilyazov A F 2010 Etiology, prevalence and characteristics of pathologies in the field of fingers at cows Holstein-frisky breed. *Urals Agrarian Bulletin* **3** (69) 77
 - [7] Polosin V 2014 Preparations of the series "Espuarol" - a modern solution in the treatment of animals. *Journal of Perfect Agriculture* 18
 - [8] Rukol V 2011 Prevention, and treatment of cows in diseases of the limbs. *Animal Husbandry of Russia* **11** 50
 - [9] Tyurin V G, Semenov V G, Chuchulin A V and Granatsky L N 2017 The use of therapeutic and hygienic means for the prevention of lameness and the treatment of diseases of hoofs in cattle. *Proceedings of the Kuban State Agrarian University* **5** (68) 158
 - [10] Ladanova M A, Suhovolsky O K and Dasaev I V 2013 Diagnosis of limb diseases in cattle. *Questions of normative-legal regulation in veterinary medicine* **3** 65
 - [11] Semenov V G and Chuchulin A V 2016 System of prevention of lameness and therapy of diseases of hooves in cows. *Scientific notes of the Kazan State Academy of Veterinary Medicine named after N.E. Bauman* **226** (2) 147
 - [12] Döpfer D, Koopmans A, Meijer F A, Szakall I, Schukken Y H, Klee W, Bosma R B, Cornelisse J L and van Asten A M 1997 Histological and bacteriological evaluation of digital dermatitis in cattle, with special reference to spirochaetes and *Campylobacter faecalis*. *Vet. Rec.* **140** 620
 - [13] Sprecher D J, Hostetler D E and J B Kaneene 1997 Locomotion Scoring of Dairy Cattle. *Theriogenology* **47** 1178
 - [14] Döpfer D, Holzhauser M and van Boven M 2012 The dynamics of digital dermatitis in populations of dairy cattle: Model-based estimates of transition rates and implications for control. *Vet. J.* **193** 648